

# MR Findings of Intramedullary Lesions : Differential Features between Tumorous and Nontumorous Lesions

Hye-Young Choi · Hyon-Joo Kwag · Jun-Hyek Song\*

*Department of Radiology,\* Neurosurgery, Neurology Division, Ewha Medical Research Center,  
College of Medicine, Ewha Womans University*

= 국문 초록 =

## 척수내 병소의 자기공명영상 소견 : 종양과 비종양성 병소의 감별

이화여자대학교 의과대학 의과학연구소 신경학부, 방사선과학교실,\* 신경외과학교실  
최혜영 · 광현주 · 송준혁\*

**목 적 :** 척수내 병소의 자기공명영상(magnetic resonance image, MRI)을 분석하고 척수내 종양과 비종양성 병소(횡단성 척수염)와의 감별진단에 도움이 될 특징적인 소견이 있는지 알아보려고 하였다.

**방법 및 대상 :** 횡단성 척수염 15예와 척수내 종양 9예의 MR image를 후향적으로 분석하였다. 진단은 11예의 횡단성 척수염 환자에서는 임상 양상과 추적 MR image로 하였고 4예의 횡단성 척수염과 모든 척수내 종양 환자에서는 수술로 확진하였다. MR 소견은 병소의 범위, 신호강도, 조영증강 양상, 특히 양쪽끝의 모양과 조영증강되는 부위의 T2WI에서의 신호강도를 중심으로 보았고 더불어서 출혈, 낭성 변화, 척수공동의 유무를 분석하였다.

**결 과 :** 횡단성 척수염은 척수내 종양보다 더 긴 분절을 침범하고 T1WI에서 동등 신호강도, T2WI에서는 고 신호강도를 보였으며 척수내 종양은 T1WI와 T2WI에서 다양한 신호강도를 보이고 3예에서 종양내 낭성 변화, 5예에서 출혈, 7예에서 척수공동을 보였다. 횡단성 척수염의 조영증강 양상은 척수내 종양에서 보다 다양하여 8예에서 결절형, 6예에서 반결형, 4예에서 선형, 2예에서 점상형, 1예에서 환형의 소견을 보였다. 12예의 횡단성 척수염은 T2WI에서 고 신호강도의 병소로 보였고 양쪽 끝이 부드럽게 가늘어지는 것을 보았고 조영증강이 되는 부위에 T2WI에서 주위와 다른 신호강도는 없었다. 이와는 달리 척수내 종양에서는 양쪽 끝이 반월상이었고 조영증강이 되는 부위에 T2WI에서 비정상적인 신호강도가 보였다.

**결 론 :** 횡단성 척수염의 T2WI는 특징적인 소견을 보여 척수내 종양과의 감별에 도움이 되며 이로써 수술 등의 침습적인 처치를 피할 수 있을 것이다.

**KEY WORDS :** Intramedullary tumors · Transverse myelitis · MRI.

## Introduction

Transverse myelitis is a monophasic inflammatory demyelinating disease of the spinal cord and does not need a surgical treatment, however intramedullary tumors are surgical candidates. Sometimes differential diagnosis between tumorous lesions and nontumorous lesions (transverse myelitis) of intramedullary lesions is difficult, especially nodular enhancement pattern is prominent.

We performed this study to evaluate the magnetic resonance (MR) images of intramedullary lesions and determine the characteristic findings between tumorous and nontumorous lesions for differential diagnosis.

## Materials and Methods

We experienced 9 intramedullary tumors and 15 transverse myelitis from March 1993 to June 1995. Using MR instrument is 1.5 T GE Signa and performed sequences are fast spin echo pre- and post-enhanced T1-weighted (T1W) and T2-weighted (T2W) images. For enhancement, we used gadolinium-DTPA with 0.1 mmol/kg body weight.

Nine intramedullary tumors were 5 astrocytoma, 2 ependymoma, 1 hemangioblastoma, and 1 cavernoma. The diagnosis was based on both the clinical and follow up MR images in 11 transverse myelitis, and by operation in 4 of transverse myelitis and all of tumors.

The MR features were specifically analyzed for extent, signal intensity, and enhancement pattern, especially the shape of both ends and signal intensity of enhancing lesion on T2WI. In addition, the presence of hemorrhage, cyst, and syrinx were also evaluated.

## Results

Transverse myelitis were involved long segment of cord than tumors and showed diffuse isosignal on T1WI and high signal intensity on T2WI (Fig. 1), but the tumors revealed variable signal intensities on both T1WI and T2WI with intratumoral cyst in 3, hemorrhage in 5 and syrinx in 7 cases (Fig. 2). The enhancement patterns of the transverse myelitis were variable (nodular in 8, patchy in 6, linear in 4, punctate in 2, ring in 1) rather than ones of tumors (Fig. 3). Especially on T2WI, the both ends of the high signal lesion of transverse myelitis were smooth tapered appearance (12/15) and there were no detectable different signals on T

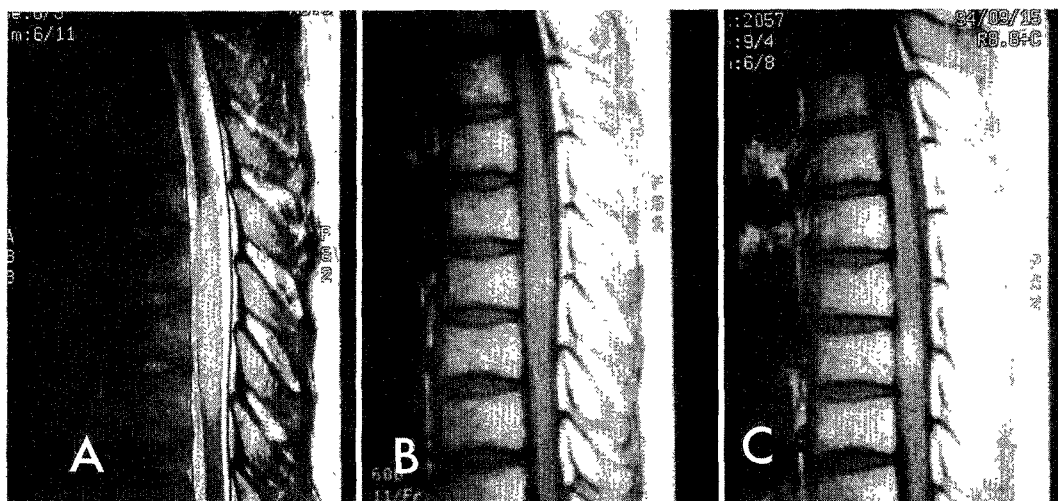
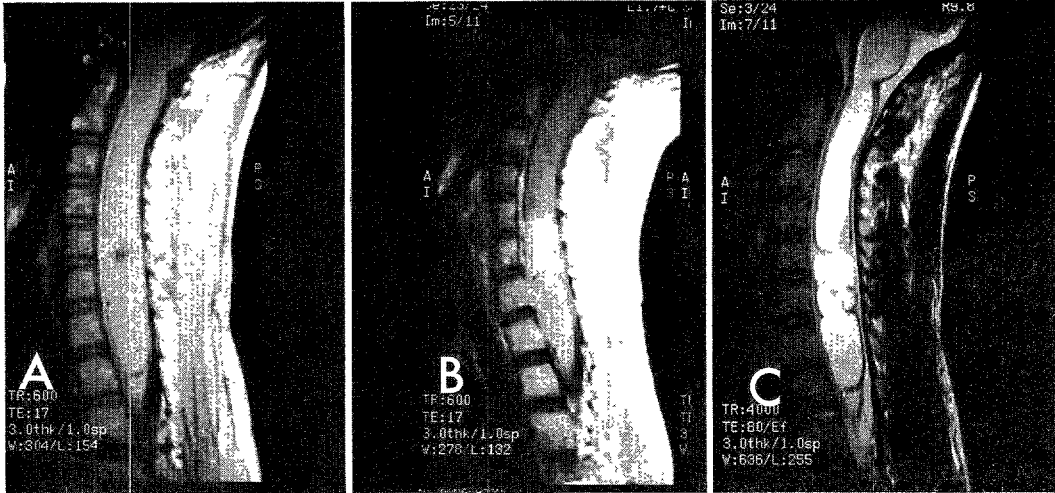


Fig. 1. 34-year-old male with transverse myelitis (surgically proved). T2-weighted sagittal MR image (A) shows diffuse homogenous high signal lesion in the spinal cord from T6 to T9 level that has tapered appearance at both ends. There is no syrinx, cyst, or hemorrhage in and around the lesion. T1-weighted sagittal MR image (B) shows diffuse cord swelling at the corresponding area of high signal lesion on T2-weighted image (arrows). Contrast enhanced T1-weighted sagittal MR image (C) shows focal enhancing nodule at the T8 level of the spinal cord.

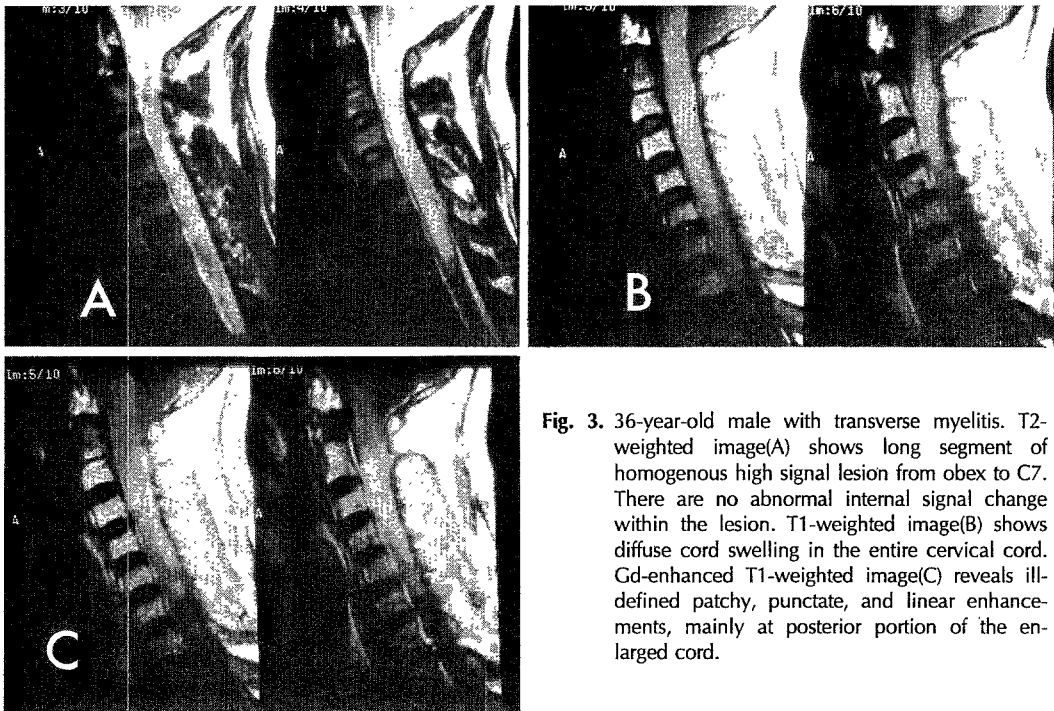
2WI at the corresponding site of enhancing areas(Fig. 1). However, both ends of the tumors were meniscal in shape and abnormal signal intensities were seen on T 2WI at the enhancing areas(Fig. 4).

## Discussion

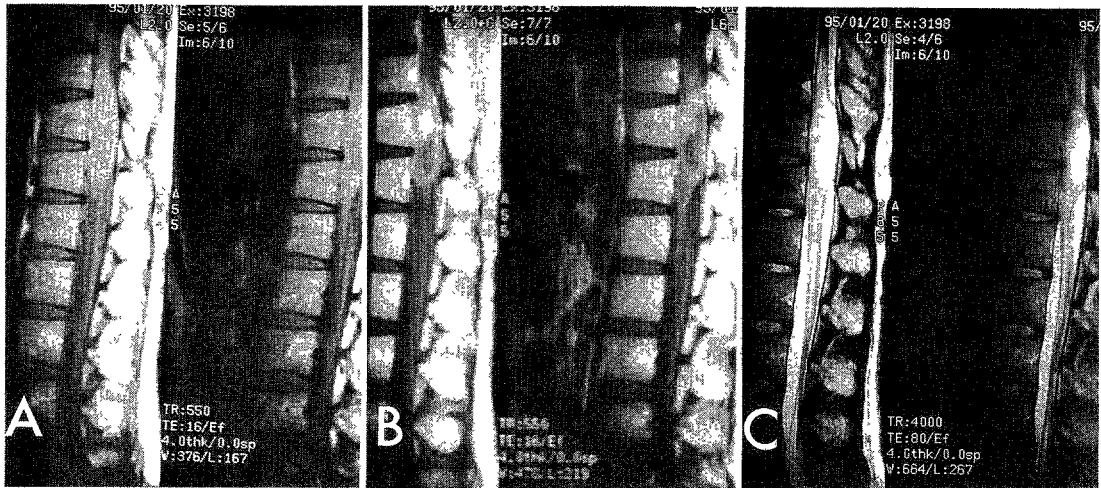
Transverse myelitis is uncommon but not rare condition occurring in all age<sup>1)</sup>. The criteria for diagnosis



**Fig. 2.** 16-year-old male with anaplastic astrocytoma with hemorrhage. On T1WI(A), cervical spinal cord is diffusely enlarged from obex to T2. Ill-defined lower signal intensity mass is seen at the level between C5 and C6 with central more dark signal lesion and surrounding more high signal lesion. Gd-enhanced T1WI(B) shows patchy enhancing lesions at the level between C5 and C6 and some ill-defined enhancements at the posterior margin of caudal syrinx, due to tumor invasion. On T2WI(C), the main mass reveals multiple high signal lesions which cannot be differentiated between peritumoral cysts and mass itself.



**Fig. 3.** 36-year-old male with transverse myelitis. T2-weighted image(A) shows long segment of homogenous high signal lesion from obex to C7. There are no abnormal internal signal change within the lesion. T1-weighted image(B) shows diffuse cord swelling in the entire cervical cord. Gd-enhanced T1-weighted image(C) reveals ill-defined patchy, punctate, and linear enhancements, mainly at posterior portion of the enlarged cord.



**Fig. 4.** 32-year-old female with anaplastic astrocytoma. T1-weighted image(A) shows oval shaped well-defined mass at the cornu medullaris area with inhomogenous signal intensities. Enhanced T1-weighted image(B) shows enhancing nodular lesion at the corresponding site of isosignal intensity on pre-enhanced image. Peripheral ring enhancement is also noted at the margin of the tumor. T2-weighted image(C) demonstrates high signal intensity of intratumoral cystic area, which is well correlated with low signal portion on T1-weighted image.

of transverse myelitis is as follows ; 1) Sudden onset of rapidly increasing weakness of the extremities, sensory impairment, and loss of rectal and bladder sphincter control. 2) No evidence of compressive spinal cord lesion. 3) No evidence of multiple sclerosis, tumor, arteriovenous malformation, and sarcoidosis. 4) Less than 4 weeks of symptom duration<sup>2</sup>.

The MR images of transverse myelitis is diffuse swelling of spinal cord on T1WI and homogenous high signal intensity with tapered both ends on T2WI. The enhancement patterns of transverse myelitis are variable and differential diagnosis between transverse myelitis and intramedullary tumor is often difficult, especially when the enhancement pattern is nodular. On T2WI, abnormal signal intensity is not seen in enhancing area of the Gd-enhanced scan. No evidence of cyst, hemorrhage, and syrinx is noted in the lesion of transverse myelitis.

About 90% of all spinal cord tumors are gliomas and over 95% of the spinal cord gliomas are ependymoma and low grade astrocytoma<sup>34</sup>. Other primary spinal cord tumors such as hemangioblastoma and cavernoma are rare. The characteristic findings of intramedullary tumors are meniscal shape of both

ends, abnormal signal intensities on T2WI at the corresponding area of enhancement, and intratumoral hemorrhage, cyst, and syrinx<sup>56</sup>. One case of ependymoma shows specific finding of dark signal rim, suggesting hemosiderin rim, on both ends of the lesion<sup>7</sup>. The MR images of hemangioblastoma and cavernoma are specific because of multiple feeding vessels on hemangioblastoma and hemosiderin rim and variable staged hemorrhage on cavernoma<sup>89</sup>.

Segmental cord swelling, diffuse high signal intensity with tapered appearance of both cranial and caudal ends, no evidence of cyst, hemorrhage, syrinx, and no focal abnormal signal intensity that is compatible with the enhancing lesion suggest transverse myelitis. Therefore, if above MR findings are seen, follow-up study is recommended to avoid the invasive surgical procedure.

## Summary

Purpose :

To evaluate the magnetic resonance(MR) images of intramedullary lesions and determine the characteristic findings between intramedullary tumors and

nontumorous(transverse myelitis) lesions for helping the differential diagnosis.

Materials and Methods :

The MR images of 15 patients of transverse myelitis (TM) and 9 patients of intramedullary tumor were retrospectively reviewed. The MR features were specifically analyzed for extent, signal intensity, and enhancement pattern, especially shape of both ends and signal intensity of enhancing lesions on T2WI. In addition, the presence of hemorrhage, cyst, and syrinx were also evaluated.

Results :

TM was involved long segment of cord than tumors and showed diffuse isosignal on T1WI and high signal intensity on T2WI, but the tumors revealed variable signal intensities on T1- and T2WI with intratumoral cyst in 3, hemorrhage in 5 and syrinx in 7 cases. The enhancement pattern of the TM were variable than ones one of the tumors. On T2WI, most of the TM(12/15) showed smooth tapered appearance at both ends of the high signal intensity lesions and all revealed no detectable different signals corresponding site of enhancing areas instead of tumors which showed meniscal shape at both ends and abnormal signal intensities at the enhancing areas.

Conclusion :

We concluded that T2W images of TM showed the characteristic findings which could differentiate from intramedullary tumors and avoid invasive surgical procedure.

## References

- 1) Shen WC, Lee SK, Ho YJ, Lee KR, Mak SC, Chi CS : *MR of sequale of transverse myelitis. Pediatr Neurol* 1992 ; 22 : 382-383
- 2) Jeffery DR, Mandler RN, Davis LE : *Transverse myelitis : Retrospective analysis of 33 cases, with differentiation of cases associated with multiple sclerosis and parainfectious events. Arch Neurol* 1993 ; 50 : 532-535
- 3) McCormick PC, Torres R, Post KD, Stein BM : *Computed tomography and magnetic resonance imaging of intramedullary spinal cord tumors. Acta Radiol* 1986 ; 369 : 738-740
- 4) Rubinstein LJ : *Tumors of the central nervous system. In : Rubinstein LJ, ed. Atlas of tumor pathology. Washington, DC : United States Armed Forces Institute of Pathology* 1972 : 10-12
- 5) Casin M, Gandon Y, Rolland Y, Simon J : *MRI of the spinal cord : Intramedullary tumors. J Neur* 1987 ; 14 : 337-349
- 6) Williams AL, Haughton VM, Pojunas KW, et al : *Differentiation of intramedullary neoplasms and cysts by MR. AJR* 1987 ; 149 : 159-164
- 7) Nemoto Y, Inoue Y, Tashiro T, et al : *Intramedullary spinal cord tumors : Significance of associated hemorrhage at MR imaging. Radiology* 1992 ; 182 : 793-796
- 8) Rusell DS, Rubinstein LJ : *Tumors of vascular origin. In : Russel DS, Rubinstein LS, eds. Pathology of tumors of the nervous system. London : Edward Arnold* 1989 : 639-663
- 9) McCormick PC, Michelsen WJ, Post KD, et al : *Cavernous malformations of the spinal cord. Neurosurgery* 1988 ; 23 : 459-463