

## Review

### **Return to sports following arthroscopic Bankart repair: a narrative review**

Running title: Return to sports

Erica Kholinne<sup>1</sup>, Mitchel<sup>2</sup>, Karina Sylvana Gani<sup>2</sup>, Shafira Widya Utami<sup>1</sup>, Savina Rifky Pratiwi<sup>1</sup>

<sup>1</sup>Department of Orthopedic Surgery, Saint Carolus Hospital, Faculty of Medicine, Trisakti University, Jakarta, Indonesia

<sup>2</sup>Faculty of Medicine and Health Sciences, Atma Jaya Catholic University of Indonesia, Jakarta, Indonesia

Corresponding author: Erica Kholinne

Faculty of Medicine, Trisakti University, Jakarta, Gatam Institute, Eka Hospital, Indonesia

E-mail: [erica@trisakti.ac.id](mailto:erica@trisakti.ac.id)

## *Abstract*

A Bankart lesion is a tear of the labrum, the ring of cartilage that encircles the shoulder joint socket, that can occur when the shoulder is dislocated. This injury frequently affects young athletes and is associated with shoulder instability. This review was performed to provide an overview of anterior shoulder instability, with an emphasis on rehabilitation and the return to sports following arthroscopic Bankart repair. We searched the Google Scholar and PubMed academic databases through February 18th, 2024, utilizing keywords including “arthroscopic Bankart repair” and “return to sports”. Our findings indicate that athletes who undergo arthroscopic Bankart repair exhibit higher rates of returning to sports compared to those who receive other anterior shoulder stabilization procedures. Several factors are considered when determining readiness to return to athletics, including time elapsed since surgery, type of sport, strength, range of motion, pain, and proprioception. Surgeons typically advise athletes to wait approximately 6 months after surgery before resuming sports activities. They also recommend that athletes regain at least 80% of the strength of the uninjured shoulder or achieve

strength levels comparable to those prior to the injury. Additionally, patients are expected to attain a full range of motion without pain, which should be symmetrical to the uninjured side, and demonstrate improved proprioception in the shoulder. The sport in which an athlete participates can also influence the timeline for return. Those involved in overhead sports, like baseball or tennis, often experience lower success rates in returning to their sport compared to athletes from other disciplines.

**Keywords:** Bankart lesions; Joint instability; Proprioception; Return to sport; Shoulder joint

## **Introduction**

### **Background**

An efficiently functioning glenohumeral joint depends on the integrity and coordinated interaction of both static and dynamic components. The structures essential for maintaining normal shoulder function are particularly susceptible to injury and dislocation. Such dislocations frequently involve the glenoid labrum, bony rim, ligaments, capsule, and humeral head [1]. The incidence of anterior shoulder instability ranges from eight to 17 dislocations per 1000 person-years. Anterior shoulder dislocation rates are notably high among young athletes, particularly in contact sports such as football and rugby [1-5]. Anterior shoulder instability has multiple causes; however, the capsulolabral complex and Bankart lesion are commonly observed in young patients. A Bankart lesion is characterized by an anterior and inferior detachment of the labrum from the glenoid, along with capsuloligamentous injury below the equator of the glenoid [6]. Arthroscopic techniques for anterior shoulder stabilization have advanced considerably over the past two decades [7]. The outcomes of arthroscopic Bankart repair (ABR) are comparable to those of open repair in terms of recurrence rates, range of motion (ROM), and complications [8-11]. Recent studies have indicated that athletes undergoing ABR exhibit a higher rate of return to sport (RTS) compared to those treated with other anterior shoulder stabilization methods [12]. However, the rate at which athletes experience RTS following ABR varies widely among individual studies [13].

### **Objectives**

This review was conducted to summarize anterior shoulder instability, focusing on rehabilitation and RTS following an ABR procedure.

## **Methods**

### **Ethics statement**

The present study was a review based on a literature search; consequently, neither institutional review board approval nor informed consent was necessary.

### **Study design**

This study was a narrative review based on a search of academic databases.

### **Setting**

The study involved a literature search of the Google Scholar and PubMed databases through February 18th, 2024. Keywords and terms like “arthroscopy Bankart repair” and “return to sports” were employed. The inclusion criteria specified that articles must be written in English and assess the relationship between ABR and RTS.

## **Results**

The search yielded 11 relevant studies that satisfied the inclusion criteria (Table 1). These articles covered the timeframe from surgery to the resumption of athletic activities. Most studies suggest that athletes typically experience RTS approximately 6 months after surgery.

Table 1. Characteristics of the included studies.

No.	Study	Year	Sample (N)	Mean age (years)	Surgical technique	Return to sport
1	Hurley et al. [2]	2021	156	28 ± 8	ABR	12 weeks for contact in training, 6 months for full contact and competition
2	Harada et al. [6]	2023	50	16.8 ± 1.7	ABR	6.6 ± 2.7 months (range, 3–18 months) for return to sport, 9.3 ± 4.0 months (range, 6–24 months) for competitions, and 10.6 ± 4.3 months (range, 8–24 months) for complete return
3	Porcellini et al. [15]	2002	25	25.6	ABR	12 weeks for non-contact sports, 5 months for contact sports
4	Kelley et al. [31]	2021	62	18 ± 7	ABR	6.5 ± 0.7 months
5	Blonna et al. [32]	2016	30	> 18	ABR	3-5 months for non-collision sports, 6 months for collision sports
6	Sedeek et al. [33]		37	26.3	ABR	3 months for non-contact sports, 4 months for contact sports
7	Ide et al. [38]	2004	55	20	ABR	4 months for contact sports, 8.1 months for overhead sports, and 3.6 months for non-contact and non-overhead sports
8	Buckup et al. [40]	2018	20	27.75	ABR	6 months for non-contact and non-overhead sports, 7 months for overhead and contact sports, and 10 months for competition

9	Gibson et al. [41]	2016	34	23	ABR	11 weeks
10	Wilson et al. [42]	2020	43	18.1 ± 3.7	Arthroscopic shoulder stabilization surgery	6 months
12	Plath et al. [49]	2015	66	29.3 ± 10.4	ABR	3 months for specific training, 6 months for overhead and high-contact sports

No., number; ABR, arthroscopic Bankart repair.

## Discussion

### Bankart lesion

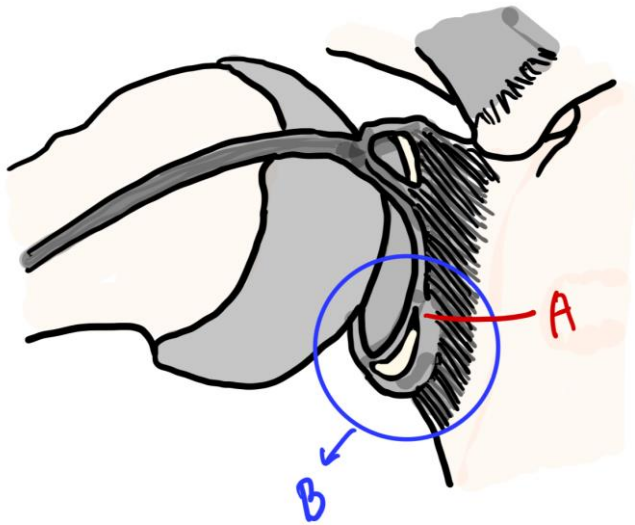


Fig. 1. (A) Labral tear. (B) Bankart lesion.

A Bankart lesion is characterized by an anterior and inferior detachment of the labrum from the glenoid, accompanied by an injury to the capsuloligamentous structures below the equator of the glenoid (Fig. 1). This type of lesion commonly results from a traumatic anterior glenohumeral dislocation and is particularly prevalent among younger individuals [14]. Additionally, a traumatic anterior glenohumeral dislocation can lead to an avulsion fracture of the anterior glenoid rim, which is

termed a bony Bankart lesion [15-17]. The extent of bone loss is a crucial determinant in the likelihood of recurrent glenohumeral instability following stabilization surgery [18].

### Mechanism of injury

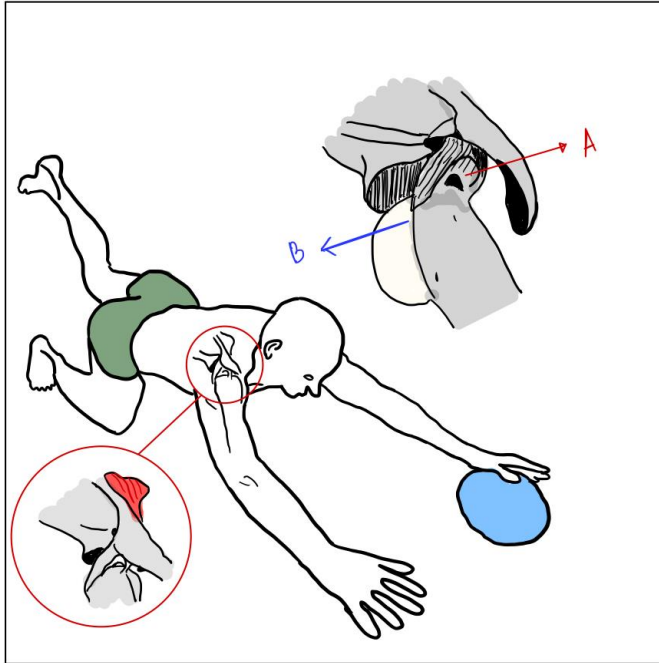


Fig. 2. Mechanism of injury in anterior shoulder dislocation resulting in (A) rotator cuff tear and (B) subluxed humerus.

Shoulder instability manifests through the disruption of the dynamic and static stabilizing elements of the glenohumeral joint, which can result in dislocation, subluxation, or a sensation of apprehension accompanied by pain. The stability of the shoulder is maintained by the glenoid labrum, the glenohumeral ligament complex, negative intra-articular pressure, and articular conformity. Furthermore, the rotator cuff and scapular stabilizers represent key dynamic contributors to shoulder restraint [1].

Anterior dislocation is the most common type of shoulder dislocation, accounting for approximately 97% of these injuries [19]. Anterior dislocation typically occurs when an individual falls with the arm abducted and externally rotated, causing the posterosuperior aspect of the humeral head to impact the anteroinferior aspect of the glenoid rim. This can result in damage to the humeral head, the glenoid labrum, or both (Fig. 2). Additionally, an indentation may develop on the humeral head

due to a compression fracture, occurring when the humeral head is forced against the anterior glenoid rim during dislocation [20]. Rotator cuff injuries can arise in more than 50% of elderly patients [21].

### **Risk factors and recurrence rate of redislocation**

Patients with a history of shoulder dislocation face an increased risk of recurrent dislocation. This often occurs due to inadequate tissue healing, laxity, and high levels of activity. Moreover, patients who have sustained rotator cuff tears or glenoid fractures are at a heightened risk of recurrent dislocation [19]. Another critical factor is glenoid bone loss exceeding 20%, which significantly contributes to recurrent anterior shoulder instability [22].

Regarding the recurrence rate of instability after ABR, research indicates a higher occurrence among younger patients [7]. In one study, patients aged 22 years or younger experienced a recurrence rate after ABR of 13.3%, whereas older patients exhibited a rate of 6.3% [23]. Similarly, another study reported a recurrence rate of 51% among contact athletes aged 18 years or younger, compared to a 12% recurrence rate in a group of 25-year-old athletes [24]. Moreover, their findings indicated that the risk of recurrence among adolescent athletes was 2.2 times greater in athletes younger than 16 years old compared to those older than 16 years. However, the recurrence rate varies based on the type of sport, with contact and collision sports—such as rugby and American football—displaying exceptionally high recurrence rates [6]. In soccer, one study reported that goalkeepers have a recurrence rate more than eight times higher than field position players and experience worse functional outcomes. Goalkeepers often stop high-velocity shots with their hands, dive with outstretched arms, and forcefully throw balls, all actions that increase their risk of shoulder injury [25].

In a retrospective study of 271 patients who underwent primary ABR for anterior shoulder instability, researchers found that off-track Hill-Sachs lesions (HSL)—those that extend medially beyond the glenoid track—were associated with a higher risk of anterior engagement and instability compared to on-track HSL. The rate of surgical revision for patients with off-track HSL was 48% at an average follow-up of 53.5 months, while the rate for those with on-track HSL was 13% at an average follow-up of 42.3 months [22]. Another study, which included 100 recreational athletes who received ABR and were followed for an average of  $12.7 \pm 2.1$  years, revealed a 19% rate of subjective

apprehension and a 19% rate of redislocation. Additionally, gradual declines were noted in clinical outcomes and sports activity levels over time. Surgeons are advised to carefully select candidates for ABR by considering risk factors such as the presence of off-track lesions, age under 20 years, and participation in contact sports [26].

The findings regarding follow-up procedures after primary anterior shoulder dislocation consistently support the use of ABR. Relative to ABR, a significantly higher recurrence rate of instability was observed after conservative treatment. Consequently, it is logical to anticipate the need for additional future procedures in patients initially treated conservatively. A key consideration is that instability frequently results in symptoms that can disrupt patients' engagement in sports activities [27].

### Rehabilitation protocol

Postoperative rehabilitation therapy is essential for promoting the recovery of shoulder motion and strength, enabling patients to resume functional activities sooner and ultimately resulting in greater patient satisfaction [27-31]. The postoperative rehabilitation guidelines reported in the literature vary considerably, and broadly accepted guidelines for rehabilitation following ABR for anterior shoulder instability do not yet exist [31]. Kelley et al. presented a postoperative rehabilitation protocol for patients who have undergone ABR, including 2 years of follow-up. The specifics of this rehabilitation protocol are detailed in Tables 2 and 3 [32].

Table 2. Rehabilitation program goals  
ROM, range of motion; TSK-11, Tampa Scale of Kinesiophobia-11.

Weeks 1 to 4 Immediate postoperative phase	<ul style="list-style-type: none"> <li>● Protect repair</li> <li>● Mitigate consequences of immobilization</li> <li>● Promote dynamic stability and proprioception</li> <li>● Reduce pain and inflammation</li> <li>● Avoid stretching</li> <li>● Avoid active external rotation, abduction, or extension</li> </ul>
Weeks 5 to 12 Intermediate phase	<ul style="list-style-type: none"> <li>● Gradually restore full ROM</li> <li>● Preserve repair integrity</li> <li>● Restore muscular strength and balance</li> <li>● Enhance neuromuscular control</li> </ul>
Weeks 13 to 21 Minimal protection phase	<ul style="list-style-type: none"> <li>● Maintain full ROM</li> <li>● Improve muscular control, strength, power, and endurance</li> </ul>



	<ul style="list-style-type: none"> <li>● Practice core stabilization and conditioning</li> <li>● Weekly functional testing begins at week 16</li> <li>● Weekly TSK-11 administration begins at week 16</li> <li>● Sport-specific training begins at week 20</li> </ul>
Weeks 22 to 26 Advance to strengthening phase	<ul style="list-style-type: none"> <li>● Maintain full ROM</li> <li>● Improve strength, power, and endurance</li> <li>● Advance functional activities</li> </ul>
Weeks 26 to 32 Return-to-sports phase	<ul style="list-style-type: none"> <li>● Enhance strength, power, and endurance</li> <li>● Pass all functional assessments (Table 2)</li> <li>● Maintain mobility</li> </ul>

Table 3. Functional assessment test

Test	Goal	Pass
a. Overhand band reach	Demonstrate functional rotator cuff activity throughout multiplanar range of motion while avoiding trapezius dominance, trunk lean, and pelvic tilt	Maintain stability
b. Closed kinetic chain extremity stability test (CKCUEST)	Measure speed, agility, and power	21 touches (male) or 23 touches (female) in 15 seconds
c. Upper extremity Y balance	Using the operative arm as a stabilizer, test mobility and stability of the extremity and core; combines scapular stability and functional range of motion with core stabilization and thoracic rotation	3 consecutive progressions
d. One-arm hop test	Focus on stable core, maximum assessment of strength, and neuromuscular coordination	5 repetitions
e. Posterior Shoulder Endurance Test (PSET)	Assess posterior rotator cuff and deltoid strength	85% of contralateral arm strength
f. Trunk stability push-up	Stabilize spine and hips in sagittal plane during upper body symmetrical motion	3 repetitions with control
g. Long arm plank ball tap	Assess stability, proprioception, and endurance	10 bidirectional taps with body control
h. Plank weight stacking	Using the operative arm as a stabilizer, assess both proprioception and stability of	4 repetitions × 1 lb

	the core and scapula	
--	----------------------	--

### RTS after ABR

ABR was identified as having the highest rate of RTS across all age groups, surpassing other stabilization procedures such as open Bankart repair, open Latarjet, and arthroscopic Latarjet procedures [6,33]. A cohort study by Blonna et al. compared 30 participants undergoing ABR with 30 participants undergoing the open Bristow-Latarjet procedure, resulting in a higher Subjective Patient Outcome for Return to Sports score in the ABR group [32]. A systematic review of 16 articles evaluated the RTS rate after various surgical anterior shoulder stabilization techniques, revealing the highest RTS rate among athletes who underwent ABR (97.5%). Other procedures examined included open Bankart repair (86.1%), open Latarjet procedure (83.6%), minimally invasive Latarjet procedure (94.0%), and ABR with remplissage (95.5%) [12].

Goals for ABR in young athletes include restoring shoulder function and enabling RTS at pre-injury levels [6]. Shoulder stabilization for Bankart lesions can be achieved through two methods: arthroscopic surgery or open surgery. Both treatments involve reattaching the torn labrum to the glenoid [34]. A review focusing on the RTS in teenagers following surgical stabilization reported an overall return rate of 95%, with 77% of patients reaching pre-injury levels of performance [6]. Various criteria were used to assess the athletes' readiness to RTS, such as time elapsed since surgery, type of sport, strength, ROM, pain, and proprioception [35,37]. The type of sport played was linked to outcomes such as RTS failure or complete RTS.

### *Time from surgery*

The most common criterion for return to play (RTP) was the time elapsed since surgery, indicating a minimum duration between the surgical procedure and the athlete's capability to RTP [36]. A retrospective study of 50 teenage athletes who underwent ABR revealed that the average time for RTS was  $6.6 \pm 2.7$  months, with a range of 3 to 18 months. The time to return to competitive play averaged  $9.3 \pm 4.0$  months (range, 6 to 24 months), while achieving a complete return to pre-injury levels took  $10.6 \pm 4.3$  months (range, 8 to 24 months) [6]. A systematic review encompassing 58 studies reported

that the timeframe for RTS post-surgery varied from 1.5 to 12 months, with a return after 6 months being the most cited duration [37]. Another systematic review, which included 34 studies, found that patients were typically allowed to RTS after a mean of 5.7 months (range, 1.9 to 32 months) following surgery [13]. More recently, a survey study involving 317 surgeons from the United States and Europe indicated that the most frequently recommended time for athletes to resume sports was 4 months after surgery. However, most of these surgeons advised waiting an additional period, most often 2 months, before granting athletes clearance to RTS [38].

### *Type of sports*

The type of shoulder sport played can influence the likelihood of RTS. Allain et al. categorized sports that place strain on the shoulder into four distinct groups, as shown in Table 4 [39].

Table 4. Types of sports involving shoulder activity

Groups of shoulder sports	
G1	Non-collision/non-overhead sports
G2	High-impact/collision sports
G3	Overhead sports
G4	Martial arts sports

A study by Ide et al. reported that overhead athletes exhibited the lowest rate of complete RTS at 68%, compared to contact athletes and non-contact/non-overhead athletes, who had respective return rates of 86% and 100% [40]. Another study suggested that athletes should only return to overhead sports after 7 months post-surgery, and they should wait until 10 months after surgery before returning to competitive sports. Additionally, it is expected that athletes who participate in overhead sports will fully recover their external rotation capacity following ABR. Failure to achieve this recovery could negatively affect sports-related outcomes [41]. Gibson et al. found that ABR, combined with an accelerated rehabilitation program, allows professional football players to RTP relatively quickly, with an average time of 11 weeks [42].

### *Strength*

Strength is a challenging parameter to measure objectively due to the influence of various factors. A total of 25 studies have incorporated muscle strength within RTS criteria, including achievement of complete strength restoration, pre-injury strength levels, at least 80% of the strength of the contralateral side, strength comparable to the contralateral side, symmetric strength in abduction and external rotation as determined by manual testing, grade 5 strength in all intrinsic and extrinsic shoulder muscles, and strength that equal to or exceeding baseline values [36]. A retrospective study assessed strength recovery post-surgery using isokinetic and isometric devices to provide an objective evaluation. However, the findings in the literature are inconsistent, and functional goals were more frequently achieved than strength criteria [43]. A systematic review investigated the strength criteria for RTS. However, the results were inconsistent, and the studies did not uniformly assess strength with the same type of device [37].

### *ROM*

The assessment of shoulder ROM involves evaluating both active and passive movements to ensure that the athlete demonstrates symmetrical, full, and sport-specific ROM without experiencing pain or apprehension [36,44].

### *Pain*

Another important factor for RTS is the assessment of pain following ABR. Pain is considered a criterion for RTS, but it always appears in conjunction with other criteria. In this context, pain has been defined as the presence of “non-painful ROM” and being “pain-free” during physical examination or participation in sports. Here, key distinctions must be made. For the general population, a complete absence of pain is not a prerequisite. However, for athletes who aim to return to their sports activities and achieve pre-injury performance levels, being pain-free is essential [37,45].

### *Proprioception*

To date, few studies have included shoulder proprioception as a criterion for RTP. Tambe et al. noted an improvement in shoulder proprioception as an RTP criterion, yet the study did not detail the specific assessment modality employed [46].

### **Rate of RTS**

The rate of RTS at pre-injury levels varies widely according to the studies available, with figures ranging from 31% to 100% [13,37,47]. Memon et al. assessed the RTS in 1,866 patients following ABR. Their study found that 82% of competitive athletes accomplished RTS, and 88% of those returned to their pre-injury levels [13]. Abdul et al. examined RTS rates after shoulder stabilization surgery and reported a 97.5% RTS rate, with an average time of 5.9 months post-ABR [12]. Harada et al. observed high RTS rates in a cohort of 50 young athletes, with nearly all participants resuming sports; 96% returned to competitive play, and 76% fully regained their pre-injury performance levels without any complaints [7]. A systematic review that included 11 studies with 392 adolescent athletes who underwent ABR revealed a 79.8% return rate to sports at pre-injury levels [48]. In the sport of soccer, the RTS rate at the same level was significantly lower for goalkeepers compared to field players [25].

### **Reason for failing to RTS**

Athletes who experience injuries often face negative psychological responses, including depression, anxiety, irritability, and a lack of confidence. These psychological reactions can affect a patient's decision to RTS, even after ABR [49]. A retrospective study evaluated patients who underwent ABR and did not RTS over a 24-month follow-up period. The study reported that 51.9% of patients harbored a persistent fear of re-injury, 25.0% believed their injury signified the natural conclusion of their athletic career, 15.4% felt that their lifestyle had changed, 11.5% experienced persistent pain, and 7.7% were unable to RTS due to other injuries [2]. In research by Tjong et al. involving 25 patients, several reasons were identified for not returning to sport after ABR, including fear of re-injury, a shift in priorities, mood disturbances, social support, and a lack of motivation [49]. Plath et al. reported that among athletes who did not RTS after ABR, the primary reasons were non-

shoulder-related factors, followed by concerns about potential re-injury [50]. A recent study underscored kinesiophobia—fear of movement—as a prevalent factor affecting patients’ psychological readiness to RTS. Psychological interventions, such as cognitive-behavioral therapy and mindfulness, have been proposed to potentially improve RTS rates in these patients [51].

## **Conclusion**

ABR results in a high percentage of athletes returning to athletic activities, leading to the development of various criteria to support the RTP. Most surgeons advise athletes to wait 6 months after surgery before resuming sports, to regain at least 80% of the strength in the contralateral limb or a level of strength comparable to that prior to the injury, to achieve a full or symmetrical ROM without pain, and to demonstrate improved shoulder proprioception. However, the type of sport also influences the rate of RTS, with overhead sports displaying the lowest return rates. While many athletes successfully return to their previous level of competition, some may experience adverse psychological responses during the process.

## **ORCID**

Erica Kholinne <https://orcid.org/0000-0002-4326-8205>

Mitchel <https://orcid.org/0009-0001-3904-0232>

Karina Sylvana Gani <https://orcid.org/0000-0001-7306-9752>

Shafira Widya Utami <https://orcid.org/0009-0003-6525-4597>

Savina Rifky Pratiwi <https://orcid.org/0009-0003-7616-575X>

## **Authors’ contributions**

Conceptualization: Mitchel

Formal Analysis: Savina RP, Shafira WU

Investigation: Mitchel, Gani KS

Methodology: Kholinne E, Savina RP

Project Administration: Shafira WU

Writing – Original Draft: Mitchel, Shafira WU, Savina RP, Gani KS

Writing – Review & Editing: Kholinne E

### **Conflict of interest**

No potential conflict of interest relevant to this article was reported.

### **Funding**

Not applicable.

### **Data availability**

Not applicable.

### **Acknowledgments**

Not applicable.

### **Supplementary materials**

Not applicable.

### **References**

1. Galvin JW, Ernat JJ, Waterman BR, Stadecker MJ, Parada SA. The Epidemiology and Natural History of Anterior Shoulder Instability. *Curr Rev Musculoskelet Med.* 2017;10(4):411–24.
2. Hurley ET, Davey MS, Mojica ES, Montgomery C, Gaafar M, Jazrawi LM, et al. Analysis of patients unable to return to play following arthroscopic Bankart repair. *Surgeon.* 2022;20(4):e158–62.
3. Owens BD, Duffey ML, Nelson BJ, DeBerardino TM, Taylor DC, Mountcastle SB. The incidence and characteristics of shoulder instability at the United States Military Academy. *Am J Sports Med.* 2007;35(7):1168–73.
4. Krøner K, Lind T, Jensen J. The epidemiology of shoulder dislocations. *Arch Orthop Trauma Surg.* 1989;108(5):288–90.

5. Simonet WT, Melton LJ, Cofield RH, Ilstrup DM. Incidence of anterior shoulder dislocation in Olmsted County, Minnesota. *Clin Orthop Relat Res.*1984;186(186):186–91.
6. Harada Y, Iwahori Y, Kajita Y, Takahashi R, Yokoya S, Sumimoto Y, et al. Return to sports after arthroscopic Bankart repair in teenage athletes: a retrospective cohort study. *BMC Musculoskelet Disord.*2023;24(1):222-80.
7. Stone GP, Pearsall AW. Return to Play After Open Bankart Repair: A Systematic Review. *Orthop J Sports Med.*2014;2(2):410-38.
8. Friedman LGM, Griesser MJ, Miniaci AA, Jones MH. Recurrent instability after revision anterior shoulder stabilization surgery. *Arthroscopy.*2014;30(3):372–81.
9. Hobby J, Griffin D, Dunbar M, Boileau P. Is arthroscopic surgery for stabilization of chronic shoulder instability as effective as open surgery? A systematic review and meta-analysis of 62 studies including 3044 arthroscopic operations. *J Bone Joint Surg Br.*2007;89(9):1188–96.
10. Ng C, Bialocerkowski A, Hinman R. Effectiveness of arthroscopic versus open surgical stabilisation for the management of traumatic anterior glenohumeral instability. *Int J Evid Based Healthc.*2007;5(2):182–207.
11. Pulavarti RS, Symes TH, Rangan A. Surgical interventions for anterior shoulder instability in adults. *Cochrane database Syst Rev.*2009;6(4):190-39.
12. Abdul-Rassoul H, Galvin JW, Curry EJ, Simon J, Li X. Return to Sport After Surgical Treatment for Anterior Shoulder Instability: A Systematic Review: Response. *Am J Sports Med.*2019;47(3):NP24–7.
13. Memon M, Kay J, Cadet ER, Shahsavar S, Simunovic N, Ayeni OR. Return to sport following arthroscopic Bankart repair: a systematic review. *J shoulder Elb Surg.*2018 Jul 1 ;27(7):1342–7.
14. Clavert P. Glenoid labrum pathology. *Orthop Traumatol Surg Res.*2015;101(1):S19–24.
15. Porcellini G, Campi F, Paladini P. Arthroscopic approach to acute bony Bankart lesion. *Arthroscopy.*2002;18(7):764–9.
16. Godin JA, Altintas B, Horan MP, Hussain ZB, Pogorzelski J, Fritz EM, et al. Midterm Results of the Bony Bankart Bridge Technique for the Treatment of Bony Bankart Lesions. *Am J Sports Med.*2019;47(1):158–64.



17. Millett PJ, Horan MP, Martetschläger F. The “bony Bankart bridge” technique for restoration of anterior shoulder stability. *Am J Sports Med.*2013;41(3):608–14.
18. Nolte PC, Elrick BP, Bernholt DL, Lacheta L, Millett PJ. The Bony Bankart: Clinical and Technical Considerations. *Sports Med Arthrosc.*2020;28(4):146–52.
19. Abrams R, Akbarnia H. Shoulder Dislocations Overview. *StatPearls.*2023;39(4):20-9.
20. Pak T, Kim AM. Anterior Glenohumeral Joint Dislocation. *StatPearls.*2023;30(5):72-14.
21. Cunningham NJ. Techniques for reduction of anteroinferior shoulder dislocation. *Emerg Med Australas.*2005;17(6):463–71.
22. Schwihla I, Wieser K, Grubhofer F, Zimmermann SM. Long-term recurrence rate in anterior shoulder instability after Bankart repair based on the on-and off-track concept. *Journal of Shoulder and Elbow Surgery.* 2023;32(2):269-75.
23. Porcellini G, Campi F, Pegreffo F, Castagna A, Paladini P. Predisposing factors for recurrent shoulder dislocation after arthroscopic treatment. *J Bone Joint Surg Am.*2009;91(11):2537–42.
24. Torrance E, Clarke CJ, Monga P, Funk L, Walton MJ. Recurrence After Arthroscopic Labral Repair for Traumatic Anterior Instability in Adolescent Rugby and Contact Athletes. *Am J Sports Med.*2018;46(12):2969–74.
25. Pasqualini I, Rossi LA, Brandariz R, Tanoira I, Fuentes N, Denard PJ, Ranalletta M. Effect of Playing Position on Return to Sport, Functional Outcomes, and Recurrence After Arthroscopic Bankart Repair in Soccer Players. *Orthopaedic Journal of Sports Medicine.* 2022;10(11):23259671221138106.
26. Kim JS, Kim SC, Park JH, Kim HG, Kim DY, Lee SM, et al. Long-term Effectiveness and Outcome-Determining Factors of Arthroscopic Bankart Repair for Recreational Sports Population: An Assessment of 100 Patients With a Mean Follow-up of 12.7 Years. 2024;52(3):594–602.
27. Hu B, Hong J, Zhu H, Yan S, Wu H. Arthroscopic Bankart repair versus conservative treatment for first-time traumatic anterior shoulder dislocation: a systematic review and meta-analysis. *Eur J Med Res.*2023;28(1):193-10.

28. DeFroda SF, Mehta N, Owens BD. Physical Therapy Protocols for Arthroscopic Bankart Repair. *Sports Health*.2018;10(3):250–8.
29. McIsaac W, Lalani A, Silveira A, Chepeha J, Luciak-Corea C, Beaupre L. Rehabilitation after arthroscopic Bankart repair: a systematic scoping review identifying important evidence gaps. *Physiotherapy*.2022;114:68–76.
30. Matache BA, Hurley ET, Wong I, Itoi E, Strauss EJ, Delaney RA, et al. Anterior Shoulder Instability Part III-Revision Surgery, Rehabilitation and Return to Play, and Clinical Follow-Up-An International Consensus Statement. *Arthroscopy*.2022;38(2):234-242.e6.
31. Kim K, Saper MG. Postoperative Management Following Arthroscopic Bankart Repair in Adolescents and Young Adults: A Systematic Review. *Arthrosc Sports Med Rehabil*.2020;2(6):e839–45.
32. Kelley TD, Clegg S, Rodenhouse P, Hinz J, Busconi BD. Functional Rehabilitation and Return to Play After Arthroscopic Surgical Stabilization for Anterior Shoulder Instability. *Sports Health*.2022;14(5):733–9.
33. Blonna D, Bellato E, Caranzano F, Assom M, Rossi R, Castoldi F. Arthroscopic Bankart Repair Versus Open Bristow-Latarjet for Shoulder Instability: A Matched-Pair Multicenter Study Focused on Return to Sport. *Am J Sports Med*.2016;44(12):3198–205.
34. M SS, K TI, H C TA. Arthroscopic Bankart repair for traumatic anterior shoulder instability with the use of suture anchors. *Orig Artic Singapore Med J*.2008;49(9):676.
35. Rossi LA, Pasqualini I, Tanoira I, Ranalletta M. Factors That Influence the Return to Sport After Arthroscopic Bankart Repair for Glenohumeral Instability. *Open access J Sports Med*.2022;13(2):35–40.
36. Griffith R, Fretes N, Bolia IK, Murray IR, Meyer J, Weber AE, et al. Return-to-Sport Criteria After Upper Extremity Surgery in Athletes-A Scoping Review, Part 1: Rotator Cuff and Shoulder Stabilization Procedures. *Orthop J Sports Med*.2021;9(8):39-19.
37. Ciccotti MC, Syed U, Hoffman R, Abboud JA, Ciccotti MG, Freedman KB. Return to Play Criteria Following Surgical Stabilization for Traumatic Anterior Shoulder Instability: A Systematic Review. *Arthroscopy*.2018;34(3):903–13.

38. Hurley ET, Matache BA, Colasanti CA, Mojica ES, Manjunath AK, Campbell KA, et al. Return to play criteria among shoulder surgeons following shoulder stabilization. *J shoulder Elb Surg.*2021;30(6):e317–21.
39. Allain J, Goutallier D, Glorion C. Long-term results of the Latarjet procedure for the treatment of anterior instability of the shoulder. *J Bone Joint Surg Am.*1998;80(6):841–52.
40. Ide J, Maeda S, Takagi K. Arthroscopic Bankart repair using suture anchors in athletes: patient selection and postoperative sports activity. *Am J Sports Med.*2004;32(8):1899–905.
41. Buckup J, Welsch F, Gramlich Y, Hoffmann R, Roessler PP, Schüttler KF, et al. Back to Sports After Arthroscopic Revision Bankart Repair. *Orthop J Sports Med.*2018;6(2):361-38.
42. Gibson J, Kerss J, Morgan C, Brownson P. Accelerated rehabilitation after arthroscopic Bankart repair in professional footballers. *Shoulder Elb.*2016;8(4):279–86.
43. Wilson KW, Popchak A, Li RT, Kane G, Lin A. Return to sport testing at 6 months after arthroscopic shoulder stabilization reveals residual strength and functional deficits. *J shoulder Elb Surg.*2020;29(7):S107–14.
44. Wilk KE, Bagwell MS, Davies GJ, Arrigo CA. Return To Sport Participation Criteria Following Shoulder Injury: A Clinical Commentary. *Int J Sports Phys Ther.*2020;15(4):624.
45. Bravi M, Fossati C, Giombini A, Macaluso A, Lazzoli JK, Santacaterina F, et al. Criteria for Return-to-Play (RTP) after Rotator Cuff Surgery: A Systematic Review of Literature. *J Clin Med.*2022;11(8):158-42.
46. Funk L, Tambe A, Badge R. Arthroscopic rotator cuff repair in elite rugby players. *Int J Shoulder Surg.*2009;3(1):8-1.
47. Stein T, Linke RD, Buckup J, Efe T, Von Eisenhart-Rothe R, Hoffmann R, et al. Shoulder sport-specific impairments after arthroscopic Bankart repair: a prospective longitudinal assessment. *Am J Sports Med.*2011;39(11):2404–14.
48. Kasik CS, Rosen MR, Saper MG, Zondervan RL. High rate of return to sport in adolescent athletes following anterior shoulder stabilisation: a systematic review. *J ISAKOS Jt Disord Orthop Sports Med.*2019;4(1):33–40.

49. Tjong VK, Devitt BM, Murnaghan ML, Ogilvie-Harris DJ, Theodoropoulos JS. A Qualitative Investigation of Return to Sport After Arthroscopic Bankart Repair: Beyond Stability. *Am J Sports Med.*2015;43(8):2005–11.
50. Plath JE, Feucht MJ, Saier T, Minzlaff P, Seppel G, Braun S, et al. Sporting Activity After Arthroscopic Bankart Repair for Chronic Glenohumeral Instability. *Arthroscopy.*2015;31(10):1996–2003.
51. Owusu-Ansah GE, Anudu EE, Ross PP, Ierulli VK, Mulcahey MK. Psychological Readiness to Return to Sport After Shoulder Instability. *JBJS reviews.* 2023;11(9):e23.