

Case report

Nontuberculous mycobacterial infection in a sporotricoid distribution in Korea: a case report

Jin Ju Lee, Yoon Jin Choi, Ji Yeon Byun, You Won Choi, Joo Young Roh, Hae Young Choi

Department of Dermatology, Ewha Womans University College of Medicine, Seoul, Korea

Corresponding author

Ji Yeon Byun

Department of Dermatology, Ewha Womans University College of Medicine, 1071 Anyangcheon-ro,
Yangcheon-gu, Seoul 07985, Korea

E-mail: [jybyun@ewha.ac.kr](mailto: jybyun@ewha.ac.kr)

Running title: Sporotricoid atypical mycobacterial infection

Abstract

Nontuberculous mycobacterial infections, which are often acquired from environmental sources such as water and soil, exhibit a variety of cutaneous manifestations that frequently lead to misdiagnoses and delays in treatment. A 77-year-old woman presented with multiple skin lesions in a sporotricoid distribution on her right leg, which persisted despite standard antibiotic treatments. Based on the skin biopsy, revealing granulomatous inflammation with acid-fast bacilli, and PCR testing, a nontuberculous mycobacterial infection was diagnosed. Antimycobacterial drug combinations, including clarithromycin, isoniazid, and rifampicin for 4 months, complete the skin lesion's clearance. This case underscores the need for heightened suspicion and the use of appropriate diagnostic techniques, including tissue biopsies and molecular methods such as PCR.

Keywords

Anti-bacterial agents; Biopsy; Nontuberculous mycobacteria; Polymerase chain reaction; Republic of Korea

Introduction

Nontuberculous mycobacterial infections are caused by mycobacteria other than *Mycobacterium tuberculosis* and *Mycobacterium leprae*. Nontuberculous mycobacteria are commonly found in the environment, particularly in water and soil, and are more frequently associated with skin diseases than *M. tuberculosis* [1]. The infections they cause present a broad spectrum of skin symptoms. Due to this diversity, these infections are often misdiagnosed, leading to delays in treatment [2].

Case presentation

Ethics statement

Informed consent for publication was obtained from the patient.

Patient information

A 77-year-old woman presented with multiple skin lesions on her right leg that had developed approximately 3 to 4 months previously. Aside from hypertension, she had no significant medical history and no known exposure to water or soil that might explain her condition.

Clinical findings

A physical examination revealed several erythematous to maroon-colored crusted deep nodules arranged in a linear pattern on her right leg (Fig. 1).

Timeline

She was initially treated for cellulitis, but her condition did not improve. Therefore, she was referred for further investigation.

Diagnostic assessment

A skin biopsy demonstrated granulomatous inflammation extending deep into the subcutaneous tissue (Fig. 2A, B). Acid-fast bacilli (AFB) were identified with Ziehl-Neelsen staining (Fig. 2C). PCR analysis for mycobacteria was also performed on the tissue specimen, and the results were positive. We used AdvanSure

TB/NTM real-time PCR (LG Chem, Seoul, Korea); however, this system cannot define the exact type of tuberculosis. Attempts to culture the nontuberculous mycobacteria, both in a mycobacteria growth indicator tube and on Lowenstein-Jensen medium, were unsuccessful.

Therapeutic intervention

Treatment began with minocycline (50 mg twice daily), leading to gradual improvement over 3 months, but was halted due to gray hyperpigmentation at the treated sites. A switch to clarithromycin (500 mg daily) led to moderate improvement, but new lesions appeared after 4 months. Therefore, the regimen was modified to include isoniazid (200 mg per day) and rifampicin (450 mg per day), leading to noticeable clinical improvement within a month.

Follow-up and outcomes

After 4 months on this regimen, the lesions completely cleared, and no relapse was noted during a 6-month follow-up.

Discussion

The prevalence of skin infections caused by nontuberculous mycobacteria appears to be increasing. These infections manifest with a range of cutaneous symptoms, such as abscesses, cellulitis, sporotrichoid nodules, ulcers, and panniculitis. The diverse nature of these symptoms makes diagnosis challenging, necessitating a high degree of suspicion in relevant clinical contexts to ensure timely identification. Nontuberculous mycobacterial infections should be suspected in patients whose skin infections are resistant to standard treatments [3].

Infections that present in a 'sporotrichoid' form are characterized by multiple lesions along the superficial lymphatic vessels, resembling the lymphangitis observed in sporotrichosis [4]. Various mycobacteria, including *Mycobacterium marinum*, *Mycobacterium kansasii*, *Mycobacterium avium* complex, and *Mycobacterium chelonae*, are known to exhibit this sporotrichoid pattern [5].

The diagnosis of mycobacterial infection necessitates tissue biopsies to evaluate the presence of AFB and to culture tissue specimens. Molecular techniques, such as PCR, are increasingly utilized to accurately identify mycobacterial pathogens in tissue samples [5]. In this instance, AFB were detected histologically,

and nontuberculous mycobacteria were confirmed through PCR, although the specific organism could not be cultured.

Treatment guidelines recommend susceptibility testing of mycobacterial isolates to optimize the choice of specific antimycobacterial drug combinations [5]. Due to the inability to isolate the causative mycobacterium, empirical treatments were administered, assuming an *M. marinum* infection, which typically demonstrates a sporotrichoid pattern. There is no standardized treatment regimen for nontuberculous mycobacterial infections, owing to the rarity of cases and the absence of controlled trials. Common regimens for *M. marinum* include tetracyclines, specifically minocycline and doxycycline, trimethoprim-sulfamethoxazole, rifampicin, and clarithromycin. For resistant cases, a combination of rifampicin and ethambutol may be employed. The duration of therapy varies based on clinical response and can last up to 1 year [6]. It is advised to continue medication for at least 4–8 weeks after lesions have disappeared [7].

In conclusion, we report a case of nontuberculous mycobacterial infection presenting with a sporotrichoid distribution. Obtaining histopathology and conducting appropriate culture or molecular tests are essential for making the diagnosis.

ORCID

Jin Ju Lee: <https://orcid.org/0000-0002-6188-6306>

Yoon Jin Choi: <https://orcid.org/0000-0002-0375-0312>

Ji Yeon Byun: <https://orcid.org/0000-0003-4519-9474>

You Won Choi: <https://orcid.org/0000-0001-6315-3889>

Joo Young Roh: <https://orcid.org/0000-0002-9878-6691>

Hae Young Choi: <https://orcid.org/0000-0003-3460-2539>

Authors' contributions

Project administration: Byun JY

Conceptualization: Byun JY, Choi YW, Roh JY, Choi HY

Methodology & data curation: Choi YW, Roh JY, Choi HY

Funding acquisition: not applicable.

Writing – original draft: Byun JY

Writing – review & editing: Lee JJ, Choi YJ, Byun JY, Choi YW, Roh JY, Choi HY

Conflict of interest

Ji Yeon Byun has been an associate editor of the *Ewha Medical Journal*; however, she was not involved in peer review process or decision making. No other potential conflict of interest relevant to this article was reported.

Funding

Not applicable.

Data availability

Not applicable.

Acknowledgments

Not applicable.

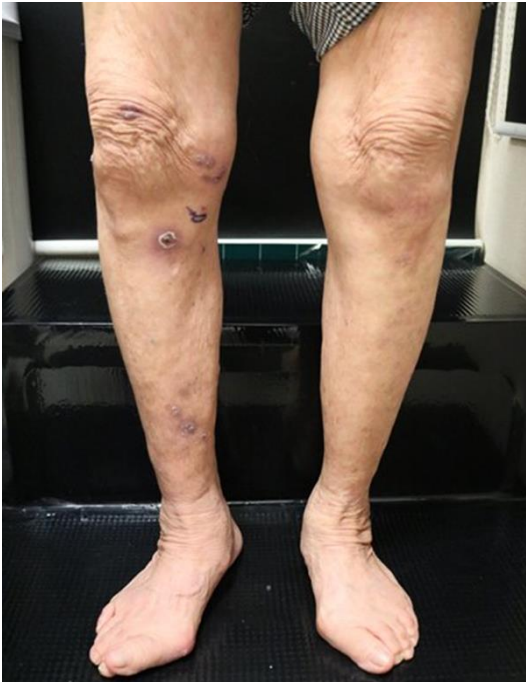Supplementary materials

Not applicable.

References

1. Sethi A. Tuberculosis and infections with atypical mycobacteria. In: Kang S, Amagai M, Bruckner AL, Enk AH, Margolis DJ, McMichael AJ, editors. Fitzpatrick's dermatology in general medicine. 9th ed. New York: McGraw-Hill; 2019.p.2870-2871.
2. Jogi R, Tying SK. Therapy of nontuberculous mycobacterial infections. *Dermatol Ther* 2004;17(6):491-498.
<https://doi.org/10.1111/j.1396-0296.2004.04051.x>
3. Gonzalez-Santiago TM, Drage LA. Nontuberculous mycobacteria: skin and soft tissue infections. *Dermatol Clin* 2015;33(3):563-577.
<https://doi.org/10.1016/j.det.2015.03.017>
4. Weedon D. Weedon's skin pathology. 3rd ed. London: Churchill Livingstone; 2010. p.560.
5. Franco-Paredes C, Marcos LA, Henao-Martínez AF, Rodríguez-Morales AJ, Villamil-Gómez WE, Gotuzzo E, et al. Cutaneous mycobacterial infections. *Clin Microbiol Rev* 2018;32(1):e00069-18.
<https://doi.org/10.1128/cmr.00069-18>
6. Palenque E. Skin disease and nontuberculous atypical mycobacteria. *Int J Dermatol* 2000;39(9):659-666.
<https://doi.org/10.1046/j.1365-4362.2000.00821.x>
7. Griffith DE, Aksamit T, Brown-Elliott BA, Catanzaro A, Daley C, Gordin F, et al. An official ATS/IDSA statement: diagnosis, treatment, and prevention of nontuberculous mycobacterial diseases. *Am J Respir Crit Care Med* 2007;175(4):367-416.
<https://doi.org/10.1164/rccm.200604-571ST>

(A)

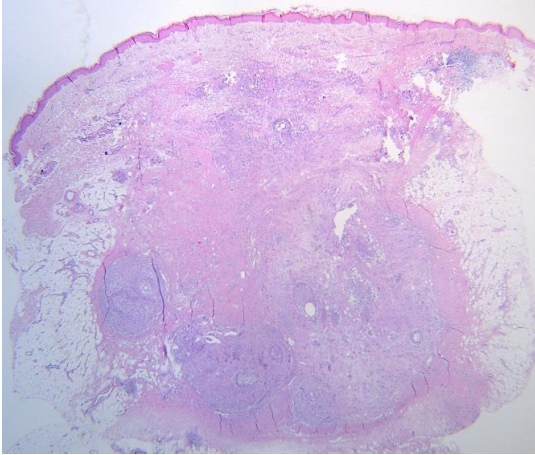


(B)

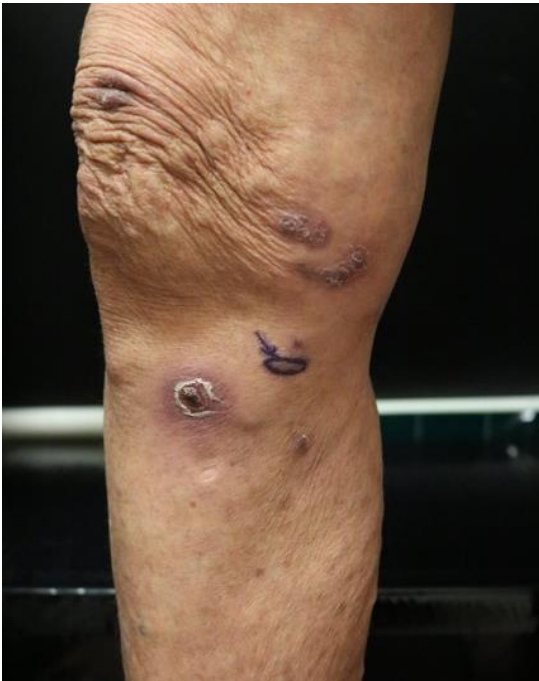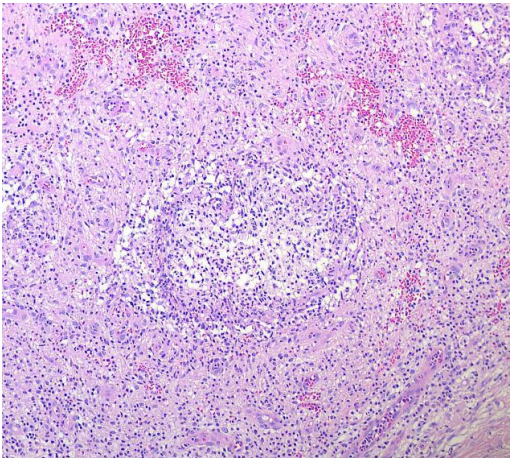


Fig. 1. Multiple erythematous to maroon-colored crusted deep nodules were arranged linearly on the right leg. Informed consent was obtained for the publication of this case report and accompanying images.

(A)



(B)



(C)

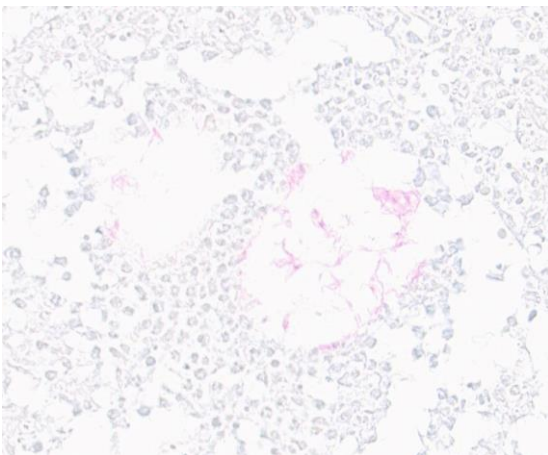


Fig. 2. Title. (A,B) Granulomatous inflammation was observed in the dermis and subcutaneous tissue (hematoxylin and eosin: A, $\times 100$; B, $\times 200$). (C) The Ziehl-Neelsen stain revealed acid-fast bacilli ($\times 400$).

Informed consent was obtained for the publication of this case report and the accompanying images.