

Case Report

Ultrasound-guided sciatic nerve block in a patient with sciatic neuropathy associated with uterine myoma: a case report

Bo Kyung Kang, Min Hyouk Beak, Won-joong Kim

Department of Anesthesiology and Pain Medicine, Ewha Womans University Mokdong Hospital, Ewha Womans University College of Medicine, Seoul, Korea

Running title: Sciatic neuropathy associated with uterine myoma

Corresponding author

Won-joong Kim

Department of Anesthesiology and Pain Medicine, Ewha Womans University Mokdong Hospital, Ewha Womans University College of Medicine, 1071 Anyangcheon-ro, Yangcheon-gu, Seoul 07985, Korea

E-mail: icaivrete@naver.com

Abstract

Although sciatica is commonly associated with lumbar spinal issues, it is important to acknowledge that non-spinal factors can also play a significant role in this condition. This is particularly relevant for female patients, in whom gynecologic conditions can lead to secondary sciatic neuropathy. Herein, we report the case of a 66-year-old woman who experienced posterolateral right lower extremity radiating pain. We initially performed a lumbar transforaminal epidural steroid injection, but the pain persisted. Subsequently, hip MRI revealed sciatic neuropathy adjacent to the pedunculated portions of a uterine myoma. We then performed a sub-gluteal sciatic nerve block under ultrasound guidance, resulting in significant relief of her pain. In conclusion, hip MRI can be helpful for the differential diagnosis of sciatica, and ultrasound-guided sciatic nerve block can be considered an appropriate and effective treatment option.

Keywords

Diagnosis, differential; Ultrasonography, interventional; Magnetic resonance imaging; Myoma; Sciatica

Introduction

Sciatica refers to pain that travels downward from the buttocks along the path of the sciatic nerve, originating from the L4 through S2 nerve roots [1]. These roots converge in the lumbosacral plexus to give rise to the peroneal and tibial nerves, which jointly form the sciatic nerve [2]. Previous studies have reported that approximately 85% of sciatica cases are associated with lumbar disc disorders [3]. The pain typically affects one side but can be bilateral, depending on factors such as disc rupture, foraminal stenosis, lumbar stenosis, and spondylolisthesis [2]. Nevertheless, although lumbar disc diseases commonly contribute to sciatica, it is crucial for clinicians to keep in mind that non-spinal factors can also play a significant role. Instances of non-spinal causes of sciatica include piriformis syndrome, zoster sine herpete, pelvic and gynecologic conditions, diabetic neuropathy, and trauma at the gluteal injection site, among others [2]. These conditions can lead to sciatic nerve compression through various mechanisms. Notably, in female patients, gynecologic issues such as intrapelvic endometriosis and tumors, as well as leiomyomas, can result in secondary sciatic neuropathy. In this context, we present a case of sciatic neuropathy in a female patient with a uterine myoma who was treated with ultrasound-guided sciatic nerve block. Informed written consent was provided by the patient for the publication of this case report and the accompanying images.

Case presentation

Ethics statement

Informed consent for publication was obtained from the patient.

Patient information

A 66-year-old woman (height, 149 cm; weight, 51.4 kg; body mass index, 23.0 kg/m²) presented to our pain clinic with a 5-month history of right hip pain and a limping gait. She reported experiencing

radiating pain in the posterolateral aspect of her right lower extremity while walking, with a numerical rating scale (NRS) score of 9 (NRS: 0=no pain, 10=worst pain imaginable). The pain was exacerbated by walking on the ground or lying on her right side and persisted even at rest. Before her referral to our hospital, she had undergone nerve blocks several times at other clinics, but they had no effect. The patient had no past medical history and was currently taking gabapentin (300 mg) and limaprost (5 µg) three times a day without pain relief.

Clinical findings

On physical examination, the active and passive ranges of motion of the hip in internal rotation were slightly decreased, but the straight leg raise test was negative on both the right and left sides. Additionally, motor and sensory examinations were intact in both lower limbs. Lumbar MRI revealed multilevel bulging discs and L4–5 degenerative spondylolisthesis, but no significant neural foraminal stenosis or central canal stenosis (Fig. 1).

Timeline

We initially diagnosed the patient with radiculopathy caused by degenerative spondylolisthesis at L4–5, and therefore, a right L5–S1 transforaminal epidural steroid injection was performed. At a 1-week follow-up, the patient's pain score decreased from NRS 9 to 7 on the right lateral thigh, but tingling and aching pain in the right buttock and posterior thigh persisted. As the patient's pain was not effectively relieved, we performed a piriformis muscle injection (0.1875% ropivacaine [5 mL], dexamethasone [5 mg]) under ultrasound guidance to rule out piriformis syndrome. After the procedure, she experienced gradual pain relief, with an NRS score of 5. We repeated the piriformis muscle injection 2 weeks later, but radiating pain in the buttock and posterior thigh remained.

Diagnostic assessment

For further evaluation, we decided to perform hip MRI and a needle EMG study. EMG did not reveal specific abnormal findings, but hip MRI showed thickening and T2 hyperintensity of the right sciatic nerve with perineural fat infiltrations extending to the sub-gluteal region. Additionally, this area was adjacent to the pedunculated portions of a uterine myoma (Fig. 2).

Therapeutic intervention

Based on the MRI findings, we planned to perform a sciatic nerve block under ultrasound guidance. The patient was in a prone position. A curvilinear transducer was then placed in the transverse plane at the lateral buttocks, and the procedure was performed slightly below the gluteal region. The transducer was placed between the greater trochanter and ischial tuberosity, and the sub-gluteal space was seen as a hypoechoic space between the hyperechoic borders of the gluteus maximus and quadratus femoris muscles, extending from the greater trochanter to the ischial tuberosity. The sciatic nerve was visualized as an oval hyperechoic structure between the greater trochanter and ischial tuberosity. Under ultrasound guidance, we performed a sub-gluteal sciatic nerve block with a mixture of 0.1875% ropivacaine (5 mL) and dexamethasone (5 mg; Fig. 3).

Follow-up and outcomes

The patient's pain was substantially relieved, reaching an NRS score of 2. She expressed dramatic pain relief after the procedure and was totally satisfied. No more aching symptoms remained when lying down or walking. Following the procedure, she was prescribed a nonsteroidal anti-inflammatory drug and antiepileptic drug for 4 weeks. At a follow-up visit 3 months later, continued symptom improvement was noted. She was advised to return if her symptoms worsened, but she did not attend any subsequent visits.

Discussion

To the best of the authors' knowledge, this is the first report of successful treatment using ultrasound-guided sciatic nerve block in a patient with sciatic neuropathy objectively confirmed to have been caused by a uterine myoma based on hip MRI.

Several cases have been reported in which a uterine myoma was identified as the cause of sciatica [1,4–6]. In those cases, despite variations in patient age, the size, number, and location of the myomas, and proximity to menopause, the common treatment for sciatica was total hysterectomy. Additionally, sciatic neuropathy was not objectively confirmed by MRI in those cases. However, in our case, hysterectomy was not indicated, and we pursued an alternative method to relieve her pain—specifically, based on the findings from hip MRI, we performed an ultrasound-guided sciatic nerve block in the targeted region.

Sciatic nerve block is categorized into parasacral, subgluteal, anterior, and popliteal approaches based on the injection region. The target for the parasacral approach is the sciatic nerve at a point distal to the lateral edge of the sacrum and caudal to the sacroiliac joint [7]. However, this approach is essentially a sacral plexus block that targets branches of the entire sacral plexus before the true sciatic nerve is formed at the inferior edge of the piriformis muscle. It is performed at the level of the greater sciatic foramen [7]. The sub-gluteal approach targets the sciatic nerve as it traverses the sub-gluteal space, located between the greater trochanter and the ischial tuberosity. This space is found between the posterior aspect of the quadratus femoris and the anterior aspect of the gluteus maximus [8,9]. In our patient, we performed a sub-gluteal sciatic nerve block at the confirmed site under ultrasound guidance. The anterior approach aims at the sciatic nerve in the proximal thigh as it descends medially to the femur, situated between the adductor magnus anteriorly and the biceps femoris and semitendinosus posteriorly. The popliteal approach targets the sciatic nerve as it divides into the common peroneal nerve and the tibial nerve in the popliteal fossa region, typically 5–12 cm from the popliteal crease [9,10].

The sciatic nerve traverses a short intrapelvic course from the pelvis, passing through the greater sciatic

foramen [11]. The sacral plexus is located on the posterior pelvic wall, anterior to the piriformis muscle, and posterior to the sigmoid colon, ureter, and internal iliac vessels. Due to its close proximity to the piriformis, the sciatic nerve is susceptible to irritation and entrapment [12]. According to a previous report, in cases of sciatica associated with obstetrical gynecological disorders, endometriosis is the most common cause, followed by factors related to pregnancy and labor, fibroids, sacral osteophytes, endosalpingiosis, needle interventions, pelvic metastasis, piriformis-related sciatica, and singular cases involving adenomyosis, intrauterine devices, hematocolpos, tubo-ovarian abscesses, and retroverted uterus [13].

The treatment approach for uterine myomas is influenced by various considerations. Relatively novel, less-invasive approaches are options, alongside pharmacological therapy, conventional surgical methods, and expectant management. Surgical procedures are considered if the patient exhibits abnormal uterine bleeding that fails to respond to conservative management, or if there is strong suspicion of pelvic malignancy, myoma growth after menopause, distortion of the endometrial cavity in infertile women, pain or pressure symptoms that diminish quality of life, or anemia resulting from chronic uterine blood loss [14]. In this case, our patient did not experience abnormal uterine bleeding, but did report radiating lower extremity pain. She was not a candidate for surgery; therefore, we planned an ultrasound-guided sciatic nerve block.

It is challenging to accurately explain why pain relief was achieved after just one sciatic nerve block without treating the causative disease. Even a single nerve block using a local anesthetic can provide lasting pain relief, which is attributed to neuroplasticity [15]. This likely applies to our case as well. Additionally, this patient underwent piriformis muscle injections twice before the sub-gluteal sciatic nerve block. During piriformis muscle injections, the medication can spread to the sciatic nerve, leading to a parasacral sciatic nerve block. This may explain why the patient's symptoms were somewhat alleviated after the piriformis muscle injections. In other words, although the patient only underwent one sub-gluteal sciatic nerve block, it can be considered that she experienced repeated sciatic nerve blocks as a result of the spread of medication during the previous injections.

In conclusion, when female patients experience radiating pain that does not respond as expected to lumbar treatment, it is crucial to consider the possibility of gynecologic problems in the differential diagnosis of sciatica. Hip MRI can be helpful for diagnosis, and if surgical treatment is not indicated, ultrasound-guided sciatic nerve block can be an appropriate and effective treatment option.

ORCID

Bo Kyung Kang: <https://orcid.org/0000-0003-2744-1044>

Min Hyouk Beak: <http://orcid.org/0000-0005-8439-6552>

Won-joong Kim: <https://orcid.org/0000-0003-2046-8690>

Authors' contributions

Project administration: Kim W

Conceptualization: Kim W

Methodology & data curation: Kang BK, Beak MH

Funding acquisition: not applicable.

Writing – original draft: Kang BK, Beak MH, Kim W

Writing – review & editing: Kang BK, Beak MH, Kim W

Conflicts of interest

No potential conflict of interest relevant to this article was reported.

Funding

Not applicable.

Data availability

Not applicable.

Acknowledgments

Not applicable.

Supplementary materials

Not applicable.

References

1. Bodack MP, Cole JC, Nagler W. Sciatic neuropathy secondary to a uterine fibroid: a case report. *Am J Phys Med Rehabil* 1999;78(2):157-159.
<https://doi.org/10.1097/00002060-199903000-00015>
2. Ropper AH, Zafonte RD. Sciatica. *N Engl J Med* 2015;372(13):1240-1248.
<https://doi.org/10.1056/NEJMra1410151>
3. Porchet F, Wietlisbach V, Burnand B, Daepfen K, Villemure JG, Vader JP. Relationship between severity of lumbar disc disease and disability scores in sciatica patients. *Neurosurgery* 2002;50(6):1253-1259.
<https://doi.org/10.1097/00006123-200206000-00014>
4. Murata Y, Takahashi K, Murakami M, Moriya H. An unusual cause of sciatic pain. *J Bone Joint Surg Br* 2001;83(1):112-113.
<https://doi.org/10.1302/0301-620x.83b1.10260>
5. Felice KJ, Donaldson JO. Lumbosacral plexopathy due to benign uterine leiomyoma. *Neurology* 1995;45(10):1943-1944.
<https://doi.org/10.1212/wnl.45.10.1943>
6. Murphy DR, Bender MI, Green G. Uterine fibroid mimicking lumbar radiculopathy: a case report. *Spine* 2010;35(24):E1435-E1437.
<https://doi.org/10.1097/BRS.0b013e3181e8ab84>
7. Mansour NY. Reevaluating the sciatic nerve block: another landmark for consideration. *Reg Anesth* 1993;18(5):322-323.
8. Karmakar MK, Kwok WH, Ho AM, Tsang K, Chui PT, Gin T. Ultrasound-guided sciatic nerve block: description of a new approach at the subgluteal space. *Br J Anaesth* 2007;98(3):390-395.
<https://doi.org/10.1093/bja/ael364>
9. Shevlin S, Johnston D, Turbitt L. The sciatic nerve block. *BJA Educ* 2020;20(9):312-320.
<https://doi.org/10.1016/j.bjae.2020.04.004>
10. Sladjana UZ, Ivan JD, Bratislav SD. Microanatomical structure of the human sciatic nerve. *Surg Radiol Anat* 2008;30(8):619-626.
<https://doi.org/10.1007/s00276-008-0386-6>
11. Salazar-Grueso E, Roos R. Sciatic endometriosis: a treatable sensorimotor mononeuropathy. *Neurology* 1986;36(10):1360-1363.

<https://doi.org/10.1212/WNL.36.10.1360>

12. Beaton LE, Anson BJ. The sciatic nerve and the piriformis muscle: their interrelation a possible cause of coccygodynia. *J Bone Joint Surg* 1938;20(3):686-688.

13. Al-Khodairy AW, Bovay P, Gobelet C. Sciatica in the female patient: anatomical considerations, aetiology and review of the literature. *Eur Spine J* 2007;16(6):721-731.

<https://doi.org/10.1007/s00586-006-0074-3>

14. Duhan N. Advances in management of uterine myomas. *Front Biosci* 2013;5(1):12-22.

<https://doi.org/10.2741/e592>

15. Petersen-Felix S, Curatolo M. Neuroplasticity: an important factor in acute and chronic pain. *Swiss Med Wkly* 2002;132(21-22):273-278.

<https://doi.org/10.4414/smw.2002.09913>

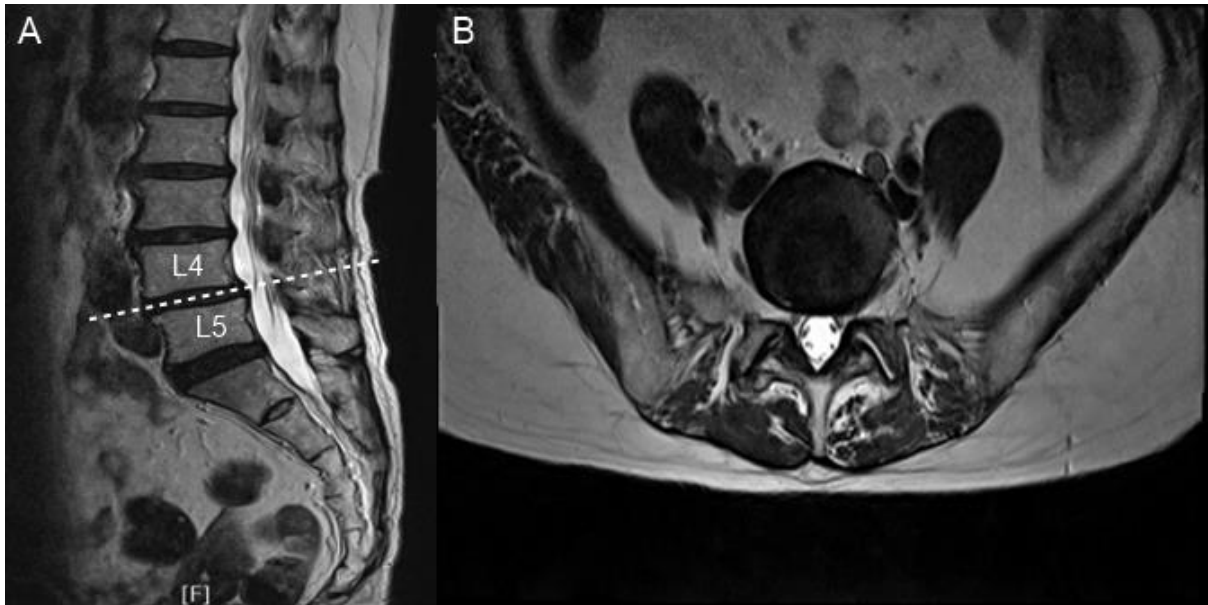


Fig. 1. Lumbar MRI. (A) Sagittal view, (B) axial view.

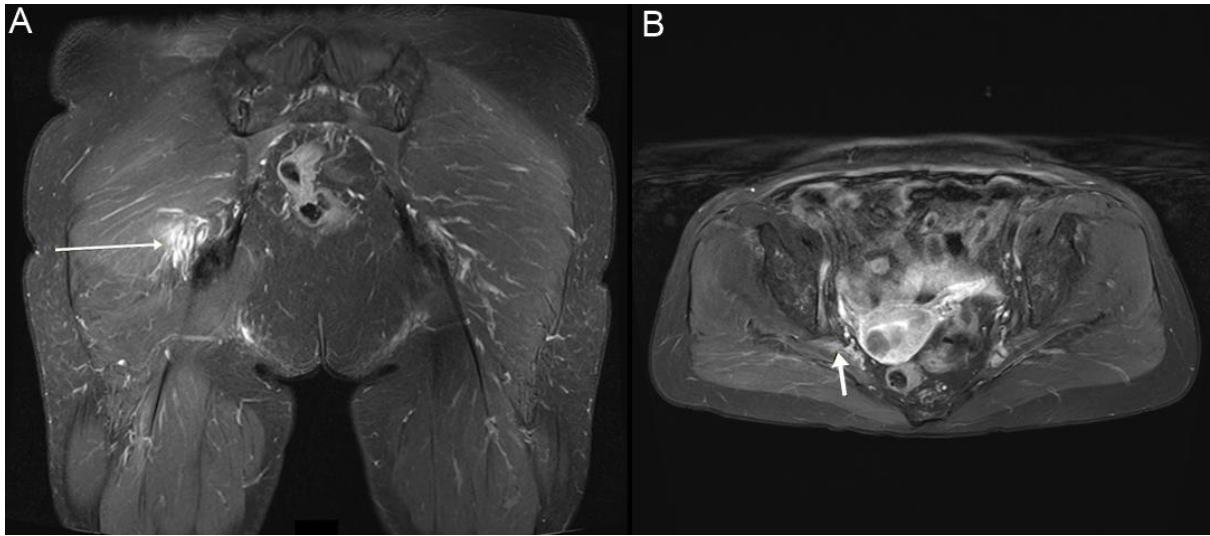


Fig. 2. Hip MRI. (A) Coronal view, (B) axial view. Arrows: sciatic nerve.

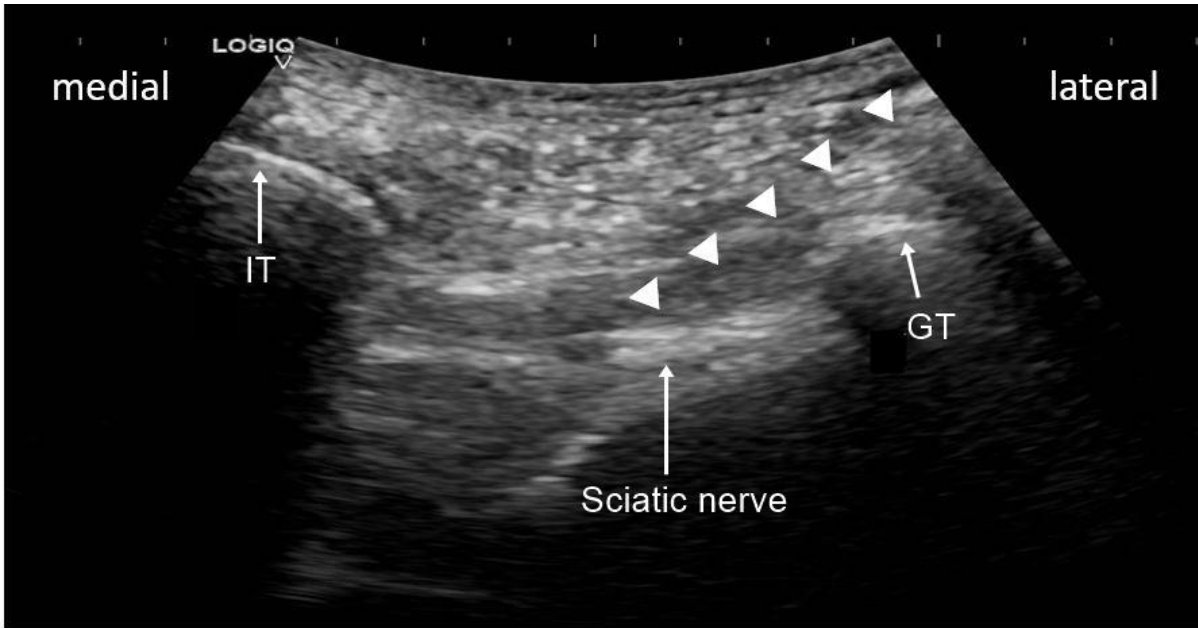


Fig. 3. Ultrasound-guided sub-gluteal sciatic nerve block. Arrowhead: needle trajectory. IT, ischial tuberosity; GT, greater trochanter.